Patient Name:	Kent , Clark	**Gender:**	Male
MRN:	2212421	**Age:**	71
Procedure Date:	11/18/2025		

Proceduralist(s): Daniel Demo, Pulmonologist, Sarah Training, MD (Fellow), Ima Fakename, MD (Fellow)

Procedure Name: Bronchoscopy

Indications: Metastatic cancer of lung, Hemoptysis

Medications:

Procedure Description: Pre-Anesthesia Assessment:
- A History and Physical has been performed. Patient meds and allergies have been reviewed. The risks and benefits of the procedure and the sedation options and risks were discussed with the patient's parent. All questions were answered and informed consent was obtained. Patient identification and proposed procedure were verified prior to the procedure by the physician, the nurse and the technician in the procedure room. Mental Status Examination: alert and oriented. Airway Examination: normal oropharyngeal airway. Respiratory Examination: clear to auscultation. CV Examination: RRR, no murmurs, no S3 or S4. ASA Grade Assessment: III - A patient with severe systemic disease. After reviewing the risks and benefits, the patient was deemed in satisfactory condition to undergo the procedure. The anesthesia plan was to use general anesthesia. Immediately prior to administration of medications, the patient was re-assessed for adequacy to receive sedatives. The heart rate, respiratory rate, oxygen saturations, blood pressure, adequacy of pulmonary ventilation, and response to care were monitored throughout the procedure. The physical status of the patient was re-assessed after the procedure.
Procedure, risks, benefits, and alternatives were explained to the patient. All questions were answered and informed consent was documented as per institutional protocol. A history and physical were performed and updated in the preprocedure assessment record. Laboratory studies and radiographs were reviewed. A time-out was performed prior to the intervention. Following intravenous medications as per the record and topical anesthesia to the upper airway and tracheobronchial tree.The Q180 slim video bronchoscope was introduced through the rigid bronchoscope (after telescope was removed) and advanced to the tracheobronchial tree of both lungs. The T180 therapeutic video bronchoscope was introduced through the and advanced to the. The procedure was accomplished without difficulty.

Findings: Left Lung Abnormalities: A partially obstructing (about 40% obstructed) airway abnormality was found in the left lower lobe. Coagulation for tumor destruction using an electrocautery snare was successful. Upon completion LLL was 100% open.

Right Lung Abnormalities: A nearly obstructing (greater than 90% obstructed) airway abnormality was found in the right lower lobe. Coagulation for tissue destruction using argon plasma at 0.3 liters/minute and 25 watts, an electrocautery probe and an electrocautery snare was successful. Upon completion both the LLL and RLL entrances were 100% open. There was residual tumor in the RLL anterior and lateral basal segments that was old and not amenable to intervention because it extended into the periphery. The RLL superior segment, RLL medial basal, and RLL posterior segment were opened 100%. Thereapeutic aspiration performed at the end of the procedure for retained blood and secretions with good hemostasis.

Complications: No immediate complications

Estimated Blood Loss: Estimated blood loss was minimal.

Post Procedure Diagnosis:
- Metastatic renal cell with left lower lobe entrance and right lower lobe entrance endobronchial tumors.
- Hemoptysis
- Partially obstructing (about 40% obstructed) airway abnormality in the left lower lobe.

Patient Name:	Kent , Clark	**Gender:**	Male
MRN:	2212421	**Age:**	71
Procedure Date:	11/18/2025		

- Nearly obstructing (greater than 90% obstructed) airway abnormality in the right lower lobe.
- No specimens collected.

Recommendation:
- Follow up with bronchoscopist in one week.
- Follow up with referring physician as previously scheduled.

Attending Participation: I was present and participated during the entire procedure, including non-key portions.

Add'l Images:

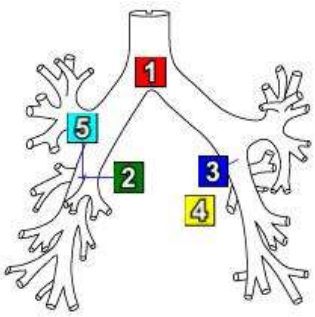

Tracheobronchial Tree

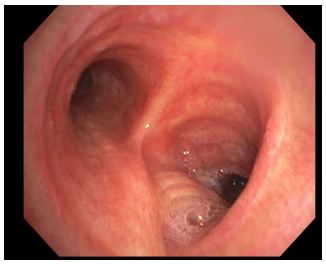

1 Carina

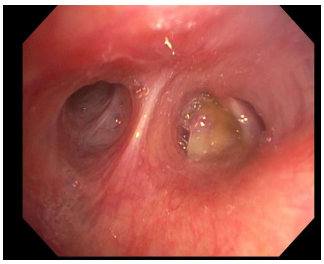

2 Right Lower Lobe

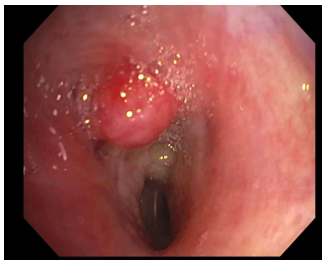

3 Left mainstem bronchus

4 Tracheobronchial tree

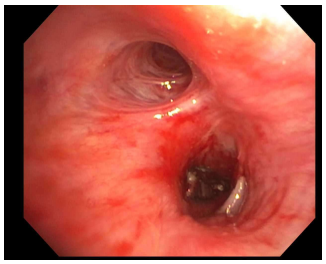

5 Right middle lobe

Daniel Demo, MD

Daniel Demo, Pulmonologist
11/18/2025 3:11:51 PM
This report has been signed electronically.

Number of Addenda: 0